

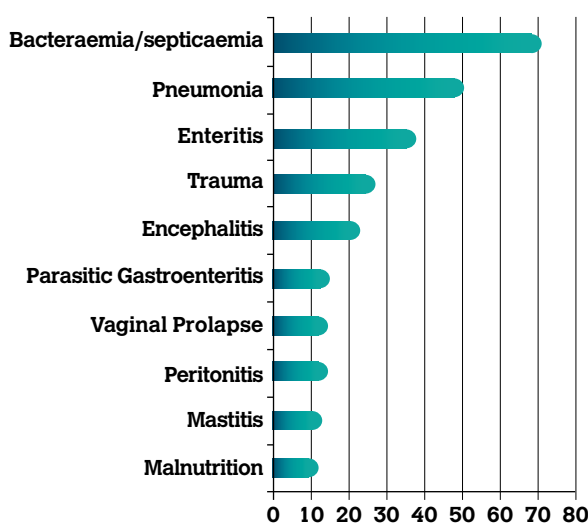
# Regional Veterinary Laboratories Report

April 2020

Regional Veterinary Laboratories (RVLs) carried out necropsy examinations on 414 carcasses and 20 fetuses during April 2020. Additionally, 1,380 diagnostic samples were tested to assist private veterinary practitioners (PVPs) with the diagnosis and control of disease in food-producing animals. This report describes a selection of cases investigated by the Department of Agriculture, Food and the Marine's (DAFM) veterinary laboratories in April 2020.

The objective of this report is to provide feedback to veterinary practitioners on the pattern of disease syndromes at this time of the year by describing common, and highlighting unusual, cases. Moreover, we aim to assist with future diagnoses, encourage thorough investigations of clinical cases, highlight available laboratory diagnostic tools and provide a better context for practitioners when interpreting laboratory reports.

## CATTLE



**Table 1: The 10 most common diagnoses in bovine carcasses submitted to DAFM RVLs in April 2020.**

## GASTROINTESTINAL TRACT

### Enteritis

A six-day-old calf was submitted to Limerick RVL. The animal had been diagnosed with an *Escherichia coli* K99 enteric infection and treated by the submitting PVP. All other affected calves had recovered. This calf had subsequently developed signs of acute abdominal pain. On post-mortem examination, a perforated ulcer with peritonitis was discovered.

A two-day-old calf was submitted to Limerick RVL with a history of severe diarrhoea. Necropsy revealed a very dehydrated carcass with very watery intestinal contents. Zinc sulphate turbidity (ZST) level was low. Cryptosporidial organisms were detected by histopathology of small intestinal sections. A diagnosis of hypogammaglobulinaemia and cryptosporidial enteritis was made.

### Johne's disease

A five-year-old cow that 'got weak over the last few days' was submitted to Kilkenny RVL. On necropsy, the carcass appeared to be in poor condition with limited internal fat depots and a wet, 'glistening' appearance of the intestines.

The intestinal walls were very oedematous, their content was liquid and the mesenteric lymph nodes were increased in size. The abomasum had a suspect cobblestone appearance, and there was oedema in the abomasal leaves (Figure 1). Histology of the abomasum showed a chronic active abomasitis with intralesional parasites confirming parasitic gastroenteritis likely due to *Ostertagia ostertagi*. Furthermore, histology revealed a granulomatous enteritis. The lymph nodes showed a granulomatous lymphadenitis with macrophage giant cells. The main differential diagnosis for this finding in intestinal sections is Johne's disease. Johne's disease with chronic parasitic gastroenteritis was diagnosed as the most likely cause of death.



**Figure 1: Abomasal fold oedema and cobblestone appearance of abomasal mucosa associated with ostertagiosis in a cow that also had Johne's disease. Photo: Aideen Kennedy.**

### Fungal reticulorumenitis

Sligo RVL received a six-week-old calf with a history of diarrhoea and unresponsive to treatment. This calf was in a large group of affected calves and there were three further deaths. Rotavirus had initially been diagnosed by a pen-side test. Post-mortem examination revealed severe dehydration and watery intestinal contents. The wall of rumen and reticulum was thickened and covered with thick caseous adhesions on the mucosa. Histopathology of ruminal and reticular sections revealed diffuse, chronic, severe, necropurulent rumenitis and reticulitis with fungal hyphae. The fungal species involved could not be identified. Fungal reticulitis and rumenitis was diagnosed as most likely cause of death. *Candida* sp. is the most commonly noted fungal pathogen in fungal reticulo-rumenitis. These infections commonly occur when there is either a change in ruminal pH or alteration of rumen microbiota.

## RESPIRATORY TRACT

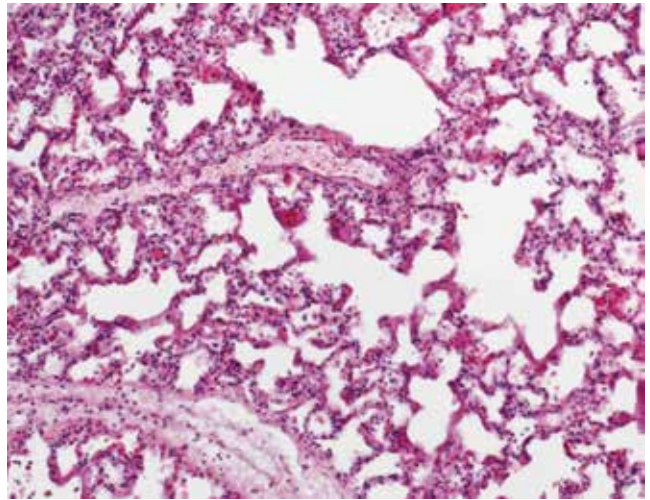
### Pneumonia

A 10-week-old calf was submitted to Kilkenny RVL with a history of ongoing respiratory symptoms unresponsive to treatment. Post-mortem examination revealed pneumonia affecting approximately 70% of the lung tissue. There was a diffuse fibrinous pleuritis with extensive adhesions to the ribcage and the pericardium. There was a pericarditis and an epicarditis. There was a moderate volume of undigested grain in the rumen. *Mannheimia haemolytica* was cultured from the lung. In addition, ruminal pH of 5.2 was recorded, indicating a likely ante-mortem ruminal acidosis. Severe pneumonia was the most significant finding in this calf.

Sligo RVL examined a one-month-old calf with a history of sudden death. On post-mortem examination, there was an enlarged friable liver with multifocal haemorrhages. The lymph nodes appeared enlarged and haemorrhagic in the cranial parts of the carcass. There was cranioventral pulmonary consolidation affecting approximately 40% of the lung parenchyma with excess of fibrinous pleural fluid. The heart appeared enlarged and flaccid. *Mycoplasma bovis*, *Pasteurella multocida* and a haemolytic *E. coli* were detected in this carcass. Kidney lead concentrations were higher than expected in normal background. Pneumonia and sepsis were diagnosed as cause of death. The significance of the presence of *Mycoplasma* in this young calf remained unclear, but the PVP and farmer were advised to consider this pathogen in future cases of respiratory disease on the holding. The cause of death in this case was likely to be secondary sepsis due to the *E. coli* or *P. multocida*. The lead result indicates possible small-scale exposure perhaps secondary to pica or aberrant eating following illness. A diagnosis of toxicity in the range observed requires good corroborative evidence such as exposure to lead material or nervous clinical signs. In this case, there is an alternative cause of death, so lead toxicity is less likely. However, pasture should be checked to ensure there is no potential source that may pose a risk to other animals and cohort animals were advised to be tested to estimate risk of exposure.

### Acute bovine pulmonary oedema and emphysema (fog fever)

A 15-month-old bovine animal was submitted to Kilkenny RVL. The animal was found dead the day before after being moved to new pasture recently. The lungs were over-inflated with multifocal areas of ground-glass emphysema and bullae. There was moderate intralobular septal oedema and the lungs had a rubbery texture. There was petechiation of the mucosal surface of the trachea but no exudate. Histopathology of the lungs diagnosed severe diffuse acute interstitial pneumonia with hyaline membrane formation and emphysema. Fog fever (acute bovine pulmonary oedema and emphysema), a key differential diagnosis for the lesions observed, was highlighted in the report issued, but viral causes could not be ruled out.

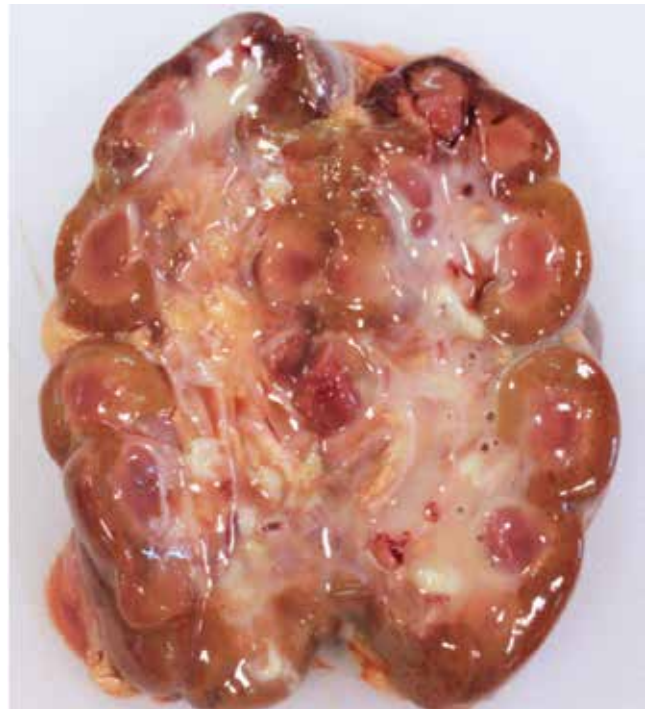

**Figure 2:** In a multifocal to coalescing pattern, hyaline membranes line alveolar walls. A differential diagnosis for these lesions includes fog fever. Photo: Maresa Sheehan.

## URINARY/REPRODUCTIVE TRACT

### Pyelonephritis

A four-day-old suckler calf was submitted to Athlone RVL with a history of having never stood up since birth and having developed diarrhoea. There had been 15 similar losses on farm in the recent past. On necropsy, the umbilicus was enlarged and infected with a tract of pus and necrotic material extending internally to the urinary bladder. Pus was present in the renal pelvis of both kidneys (Figure 3). There was consolidation of left cranial lung lobe. *E. coli* was isolated from several organs. A diagnosis of omphalophlebitis and bacteraemia leading to nephritis and pneumonia was made. Advice regarding care of the newborn calf including good hygiene and proper colostrum-feeding practices were given.



**Figure 3:** Pyelonephritis in a calf. Photo: Denise Murphy.

### MUSCULOSKELETAL

#### Joint ill

Athlone RVL examined a six-week-old calf with a history of swollen joints. There was a history of similar problems with other calves on the farm. Limb joints were visibly swollen and there was severe fibrinopurulent arthritis in the carpal, stifle and hock joints bilaterally. There was bilateral cranio-ventral pulmonary consolidation with abscessation. There was abscessation in the liver at the portal vein. *Trueperella pyogenes* was isolated from the lung and joints and *Mycoplasma bovis* was detected by polymerase chain reaction (PCR) in both the lungs and the joints. *Mycoplasma bovis* was considered the primary pathogen in this case. *Mycoplasma bovis* has been reported to cause septic arthritis, pneumonia, otitis interna in calves and can be involved in mastitis in cows.

### SYSTEMIC

#### Bacteraemia/septicaemia

A five-day-old calf was submitted to Limerick RVL with a history of sudden death. On necropsy, there was extensive perineal soiling, marked dehydration as well as pulmonary congestion and hepatomegaly. Intestinal contents were scant but watery. A faecal smear revealed large numbers of *Cryptosporidium* oocysts. *Listeria monocytogenes* was isolated from the liver and lung. A diagnosis of bacteraemia associated with *L. monocytogenes* was made, complicated by a heavy cryptosporidial infection.

### NEONATAL AND CONGENITAL CONDITIONS

#### Neonates/young calves

Two young calves were submitted to Limerick RVL from the same herd with a history of sudden death.

The first calf was four days old. Necropsy disclosed an atrial septal defect and severe congestion of all thoracic and abdominal viscera.

The second calf had died at two hours old. Necropsy disclosed a large blood clot in the abdomen associated with umbilical vessels; the calf had haemorrhaged internally after calving. Lungs and carcass were extremely pale, consistent with severe haemorrhage.

#### Atresia jejuni

Sligo RVL examined the carcass of a two-day-old calf that had been initially well after birth, but deteriorated rapidly within 24 hours, and appeared to be bloated. Post-mortem examination revealed atresia jejuni. The proximal portion of the jejunum appeared dilated and was separated by a thin membrane from the shrunken-appearing distal portion. This is a sporadically observed congenital malformation in calves, which is thought to occur following hypoxia or anoxia to a segment of gut during development. The colon is a common site for the malformation to occur but it may occur elsewhere in intestines. Severity can vary from normally formed intestines separated by a thin membrane preventing movement of ingesta, as in this case, to blind-ending intestinal segments and missing mesentery.

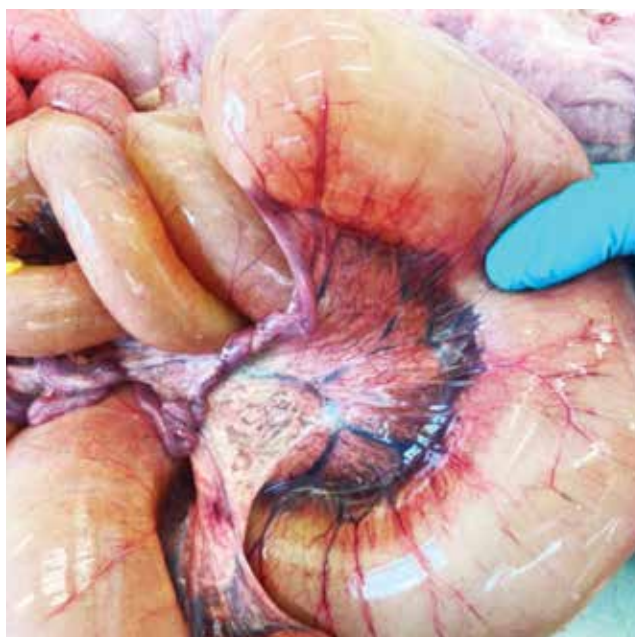

Figure 4: Atresia jejuni in a calf. Photo: Shane McGettrick.

#### Polycystic liver

Sligo RVL examined a 12-day-old calf that had presented with diarrhoea, improved initially on treatment, but was found dead. At necropsy, there was a grossly five-times enlarged and polycystic liver (Figure 5). Multifocally, the cysts contained large amounts of bile (Figure 6). The bile duct was patent at the junction to the intestine; however, the gall bladder was fibrosed and had a lobulated appearance. There was multifocal segmental thinning of intestinal mucosa. On histopathology, periportal areas appeared to be expanded by excess fibrosis and multiple variably sized coalescing and tortuous interconnected cystic structures lined by a biliary epithelium. Multifocally periportal areas compressed the surrounding hepatic parenchyma. There was bridging fibrosis between adjacent portal areas. Severe chronic enteritis was diagnosed as the cause of death. However, the predisposing cause in this calf was the presence of congenital liver cysts that would have impacted metabolic function and prevented recovery. Liver cysts in calves can occur sporadically but certain features in this case specifically the severity and the proliferation of biliary cystic structures are unusual. Bile cysts are usually solitary when described in cattle but multiple peri-biliary cysts have been reported in other species. A congenital neoplastic condition was considered but histopathology was not definitive. It is considered that the most likely cause of the condition was due to disruption of bile duct formation during foetal liver development and has been reported in other species. Congenital hepatic fibrosis is reported in cattle and frequently seen in cases submitted to RVLs but, histologically, is different to this case. However, it is possible that the biliary proliferation has a similar pathogenesis. Further characterisation and research on this unusual lesion is being carried out by DAFM pathologists.

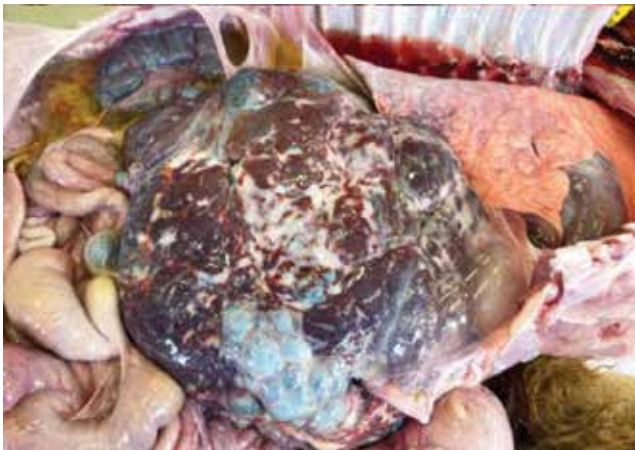

Figure 5: Enlarged fibrosed and polycystic liver in a calf. Photo: Shane McGettrick.

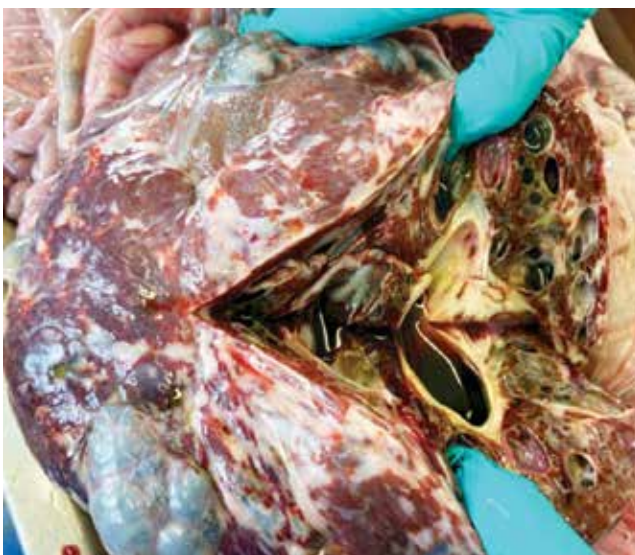

Figure 6: Opened enlarged liver in a calf demonstrating large cystic structures filled with bile. Photo: Shane McGettrick.

MISCELLANEOUS

Pharyngitis

Sligo RVL examined a 13-year-old cow that had been reported to be failing and anorexic for the previous two weeks. On post-mortem examination there was marked diffuse submandibular subcutaneous oedema. Retropharyngeal and submandibular lymph nodes were grossly enlarged with a gritty texture and multifocal areas of yellow necrosis. The retropharyngeal buccal mucosa was oedematous and the pharynx appeared partially occluded. On histopathology, there was chronic severe multifocal lymphoplasmacytic and histiocytic sialoadenitis, lymphadenitis and myositis. The pattern of observed lesion is consistent with timber tongue in pharyngeal soft tissue and in lymph nodes. *Actinobacillus lignieresii* is a likely agent but could not be definitively identified. Histology was non-specific as to aetiology. The chronicity of the lesion, the severe fibrosis and the occlusion of the pharynx are likely to have been responsible for the failed treatment. The initiating factor is likely due to trauma. The area where the lesion occurred would be consistent with a dosing-gun injury.

SHEEP

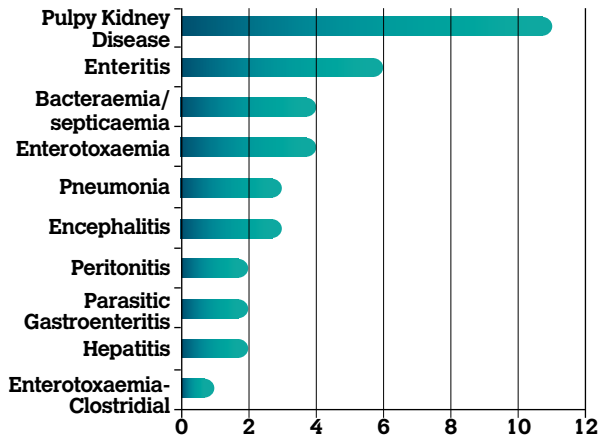


Table 2: The 10 most common diagnoses in ovine carcasses submitted to DAFM RVLs in April 2020.

GASTROINTESTINAL TRACT

Enterotoxaemia

A one-month-old lamb was submitted to Limerick RVL with a history of sudden death. Necropsy disclosed a severely congested intestinal tract. *Clostridium perfringens* and its epsilon toxin were detected by ELISA. A diagnosis of clostridial enterotoxaemia was made and vaccination with a multivalent clostridial antitoxin was recommended. Clostridial diseases were the most commonly diagnosed causes of death in sheep submitted to DAFM RVLs in this month. Clostridial vaccination is a strong recommendation for sheep flocks in Ireland.

Parasitic gastro-enteritis

*Haemonchus contortus* or 'barber's pole worm' has been diagnosed as the cause of death of a ewe from a flock in Co. Wexford. The carcass of the ewe with a history of pale gums and conjunctivae (potentially indicating significant blood loss) was submitted to Kilkenny RVL. A faecal sample from the ewe contained an estimated 24,000 strongyle eggs per gram (epg) of faeces.

*Haemonchus contortus* most commonly affects sheep and goats, but can also affect cattle. It is often called the 'barber's pole worm' due to its resemblance to a red and white spiral-patterned barber's pole when the intestine is full following a blood meal. The red intestine spirals round the pale uterus of the female giving the 'barber's pole effect'. The adult worms have a piercing lancet which facilitates extraction of blood from the blood vessels of the abomasum. The host becomes ill due to the blood-feeding activities of the adult and developing larvae. Each worm can remove about 0.05ml of blood per day so sheep and goats with 5,000 *H. contortus* worms may lose about 250ml daily; but even much lower worm burdens can cause enough blood loss to cause disease. Typical signs of infestation include paleness of gums and conjunctivae, swelling under the jaw (bottle-jaw), increased rate and depth of breathing, and an increased heart rate. Clinical signs can also include sudden death in

very acute cases, and ill-thrift in chronic cases. Diarrhoea is not a typical feature of the disease.

There is little effective immunity to *H. contortus* so, unlike the case with other parasitic diseases excluding liver fluke, adults are also at risk of haemonchosis. Control and prevention rely on regular faecal egg counts, pasture management and strategic anthelmintic use. In temperate climates like Ireland's, *H. contortus* does not tend to survive the winter in large numbers on pasture. The principal way in which it survives in flocks over winter is through the persistence of larvae in a hypobiotic (dormant) state in the gut of the host. This feature lends itself to the development of anthelmintic resistance in *H. contortus* worms, and so resistance is a common feature in flocks affected by the parasite.

The larvae of *H. contortus* develop more rapidly and successfully, and have better survivability over winter, at warm temperatures. Accordingly, the disease is much more prevalent and causes greater losses in tropical and subtropical areas than in temperate climates. With the prospect of warmer temperatures and milder winters in Ireland due to climate change, it is to be expected that the prevalence and pathogenicity of haemonchosis will increase in the years ahead, and that outbreaks causing substantial losses will become more common.

Farmers are advised to contact their PVP to discuss diagnosis, treatment and control in greater detail if they suspect haemonchosis in their flocks or herds.

Key points relating to *H. contortus* include:

- Female worms lay lots of eggs, which develop rapidly under optimal conditions;
- Relatively low numbers of worms can cause disease as it is highly pathogenic;
- Diarrhoea is not a typical feature;
- Anaemia, bottle jaw and poor thrive are key clinical signs; and
- Adult animals develop little immunity meaning adults are at risk of developing disease.



**Figure 7:** *Haemonchus contortus* worms recovered from a sheep carcass in Kilkenny RVL. Note typical barber's pole appearance.

## RESPIRATORY TRACT

### Pneumonia

Sligo RVL received a three-week old lamb that had been found dead. Three further lambs had died recently in the group. Post-mortem examination revealed pleurisy and consolidation in the right mid-lung lobe. The intestines were translucent with scant contents. *Mannheimia haemolytica* was detected in lung tissue. *Anaplasma phagocytophilum* was detected in the spleen. Severe suppurative bronchopneumonia and multifocal acute interstitial pneumonia was diagnosed on histopathology. Pneumonia with sepsis was diagnosed as cause of death.

## URINARY/REPRODUCTIVE TRACT

### Abortion

A stillborn lamb was submitted to Limerick for post-mortem examination. *L. monocytogenes* was isolated from the foetal stomach contents. A diagnosis of abortion associated with *L. monocytogenes* infection was made.

*Listeria monocytogenes* is a sporadic cause of abortion in sheep mostly towards the end of gestation. Ewes can show a range of clinical symptoms as anorexia, depression, high temperatures and septicaemia in some cases. Aborted foetuses are usually in advanced autolysis, but mummification is also possible. Necrotic areas in cotyledons and intercotyledonary areas as well as in the fetal liver can occur.

### Urolithiasis

Sligo RVL examined the carcass of a six-week-old lamb that had been observed with a shaking tail, excessive bleating, bruxism and diarrhoea. There was no improvement on veterinary treatment. The farmer reported eight further losses in the same age group. At necropsy, uroabdomen was discovered. The bladder presented with a focal area of haemorrhage. Cystitis and bladder rupture in lambs are usually caused by urolithiasis. As there were several deaths reported in the group, it was recommended to review the feeding regimen as dietary mineral inclusion rates and drinking water availability are known risk factors.

## NERVOUS SYSTEM

Sligo RVL diagnosed louping ill as the cause of death in a group of hill sheep that had recently been dipped but were displaying nervous signs. The case submitted was a three-year-old ewe described by the owner as having got slow and progressing to recumbency with tetanic spasms over three days. The gross necropsy findings were unremarkable except for a number of ticks noticed on the carcass. Histopathology of the brain identified multifocal lymphocytic encephalitis in midbrain and cerebrum with perivascular cuffing throughout all brain sections. PCR testing confirmed louping ill.

## SYSTEMIC

### Septicaemia

A lamb, age not specified, was submitted to Kilkenny RVL

with a history of lameness in the flock. A few deaths had occurred in the last week. On post-mortem examination the liver was firm. There were multifocal necrotic foci approximately 1cm in diameter randomly distributed throughout the hepatic parenchyma. The intestinal content was liquid. The mesenteric lymph nodes were mildly enlarged. *Bibersteinia trehalosi* was cultured from both the lung and liver suggesting a septicaemia.

### Pyaemia

A two-week-old lamb found dead was submitted to Sligo RVL. The carcass was severely dehydrated and the tail appeared recently docked. There were multifocal liver abscesses. The intestinal loops were segmentally reddened. A heavy coccidian spp. burden was detected in faeces. Pyaemia and parasitic enteritis were diagnosed as cause of death. The origin of the liver abscessation was unclear, but was likely to be caused by a previous bacteraemia. Liver abscessation is often associated with navel infections, but also with tail docking.

A four-week-old lamb with a history of recumbency was submitted to Sligo RVL. On necropsy an approximately 7cm sized abscess was detected in the liver. There was unilateral pleuritis. The carcass was covered in a large number of ticks. *A. phagocytophilum* was detected by PCR. The causes of the observed lesions were due to bacteraemia caused by tick pyaemia or omphalophlebitis.

Tickborne fever (TBF) is a rickettsial disease affecting the white blood cells of ruminants. The disease is transmitted by the tick *Ixodes ricinus*. The causative agent *A. phagocytophilum* infects eosinophils, neutrophils and monocytes.

After exposure to infected ticks the incubation period is approximately five to 14 days. In sheep, the main clinical finding described is acute fever, which can last a number of days with temperatures exceeding 41°C. However, the clinical signs may be variable and are not always noticed. During these febrile periods appetite is depressed, respiratory and pulse rates may be elevated and there can also be coughing. In sheep high fever occurring in animals recently moved into tick infected pastures is often the first indicator of disease. Severe leucopenia and the prolonged neutropenia serve as further indicators if animals are sampled. In some cases abortion storms can occur. In young lambs the main clinical signs are likely those of tick pyaemia. The impairment of humoral and cellular defences may increase susceptibility to a variety of other conditions including tick pyaemia, pasteurellosis, louping ill and listeriosis. Cows may show signs of depression, decreased appetite and coughing but again clinical signs may not be apparent. Abortions can occur in pregnant animals. In non-pregnant animals, the importance of TBF is usually as an exacerbation of other infections.

In cattle, the main signs are abortions, and sudden milk

drop. Respiratory signs are another common finding after the herd has been introduced to tick-infected pasture. PCR is particularly useful in the late stages of the bacteraemia as it can be difficult to detect the inclusion bodies in blood smears. Gross pathology may be unremarkable unless secondary infections have occurred. Oxytetracycline is generally regarded as the most effective treatment. Effective control can be obtained by reducing contact with the vector either through the use of acaricides or by grazing tick-free pasture. There is much uncertainty surrounding individual animal susceptibility and immune response. This is further complicated by variability of factors surrounding the presence of the tick vector, tick life cycles and climatic or environmental conditions influencing tick population and behaviour. It is generally believed animals are immune after one to two bouts of the disease. Immunity can wane rapidly however, if animals are removed from tick-infested areas.

### MISCELLANEOUS

#### Leptospirosis

Sligo RVL diagnosed haemolytic anaemia in a 14-day-old lamb submitted with a history of sudden death. The carcass was severely jaundiced and there was splenomegaly. Carcass blood was noted as watery and did not clot. The bladder did not contain any urine and the renal cortices were dark with multifocal haemorrhages in the cortex. Liver and kidney copper concentrations were within normal limits. The presentation of this lamb was unusual as haemolytic anaemia is rare in sheep due to causes other than copper poisoning which could be ruled out in this case. *Leptospira* sp was identified by PCR. Sepsis due to acute leptospirosis has been associated with haemolysis in small ruminants. Further testing is underway by DAFM pathologists to identify the significance of the lesion and to identify the *Leptospira* species involved.